

Kenalilah...



biodentalcare.com.au

Geraham bongsu ialah gigi yang terakhir tumbuh didalam mulut.

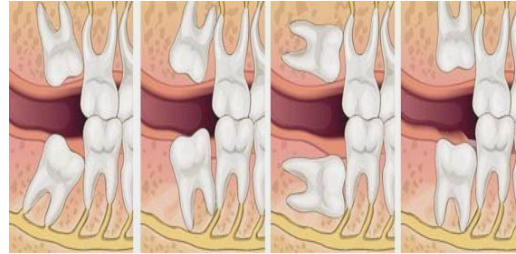
Ia adalah gigi geraham besar ketiga yang akan tumbuh dibelakang geraham besar kedua.

Pada kebiasaannya ada empat batang geraham bongsu, kadangkala ia tidak tumbuh langsung.

Masa pertumbuhan ialah diantara umur 17-25thn.

**UNIT PERGIGIAN
PUSAT KESIHATAN UiTM
SHAH ALAM**

Ruang rahang yang mencukupi tidak memberi masalah pada pertumbuhan geraham bongsu, sebaliknya ruang rahang yang sempit menghalang pertumbuhan sepenuhnya. Kemungkinan ia akan terimpak pada tulang atau gigi dihadapannya (Gbr- 1)

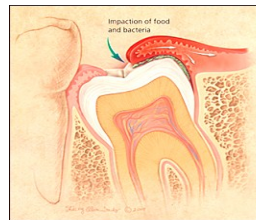


Terimpak mesial Terimpak distal Terimpak melintang Terimpak menegak

sydneycitydental.com.au

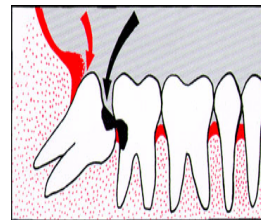
Gbr -1 Posisi Geraham Bongsu Terimpak

Apabila pertumbuhan gigi tidak normal, pembersihan gigi tidak dapat dibuat dengan sempurna, dan akan mengakibatkan infeksi pada gusi (Gbr-2) dan kerosakkan gigi /karies gigi(Gbr-3)



aafp.org

Gbr-2 infeksi gusi



dentist.com.sg

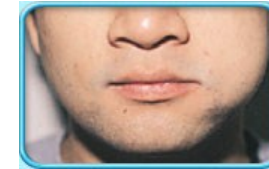Gbr-3 karies gigi

Manifestasi klinikal



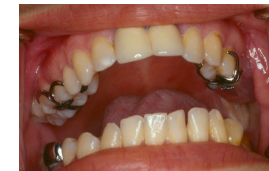dneal.com

Rasa sakit/Demam



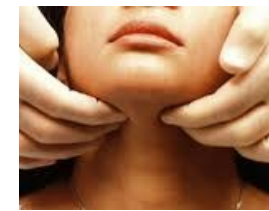toothclub.gov.hk

Bengkak pipi/selulitis



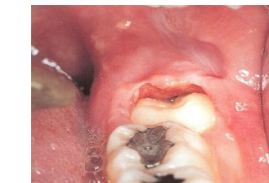toothclub.gov.hk

Kesukaran membuka mulut/menelan



dentalmedsoft.co

Nodus limfa bengkak



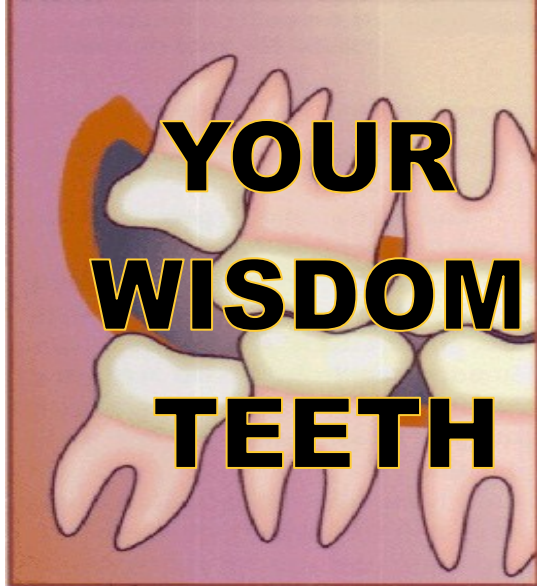
oksu.com

Bengkak gusi

Rawatan:

- Kes minor _ Berkumur air garam,ubat penahan sakit.
- Kes major - Antibiotik,ubat penahan sakit
- Kes berulang - Gigi dicabut

Know...



biodental.com.au ;

Wisdom teeth are the last teeth to erupt in the mouth.

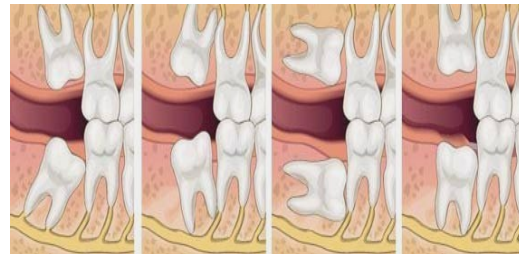These are the third permanent molars which will erupt behind the second permanent molars.

Overall there are four wisdom teeth. In some cases it will not erupt at all.

The eruption time is at the age of 17-25 years.

**DENTAL UNIT
HEALTH CENTRE UiTM
SHAH ALAM**

A sufficient jaw space will cause no problem in eruption of wisdom teeth. However, an insufficient jaw space will hinder the normal eruption of the teeth. Consequently, it can cause impaction to the bone or tooth in front. (Pic-1)

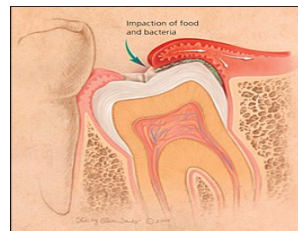


Mesial Impacted Distal Impacted Horizontal Impacted Vertical Impacted

sydneycitydental.com.au

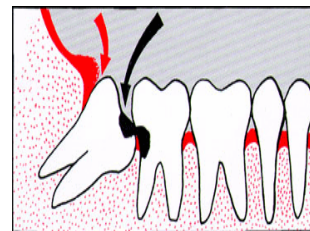
Pic-1 Position of impacted wisdom teeth

The abnormal position of the teeth will cause difficulty in brushing and will result in gum infection (Pic-2) or teeth decay (Pic-3)



aafp.org

Pic-2 gum infection.



dentist.com.sg

Pic-3 teeth decay

Clinical Manifestation



dneal.com

Pain/ Fever



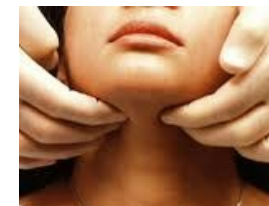toothclub.gov.hk

Cheek swelling/ Cellulitis



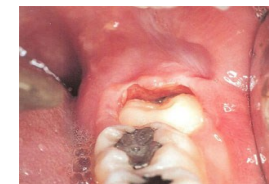toothclub.gov.hk

Difficulty in mouth opening/ swallowing



dentalmedsoft.co

Lymph node enlargement



oksu.com

Gum swollen

Treatment:

- Minor cases : Warm salt water gargle, painkiller
- Major cases : Antibiotic, painkiller
- Recurrent cases : Extraction of teeth